

Abstract Number: PP-026

INTRANASAL BEVACIZUMAB TREATMENT ON EPISTAXIS IN HEREDITARY HAEMORRHAGIC TELANGIECTASIA: A CASE REPORT

García Martín E, Pernía López MS, Monje B, Martínez Ortega PA, Ortega Navarro C, Revuelta JL, Ruiz Martínez C, Herranz Alonso A, Sanjurjo Sáez M.

Servicio de Farmacia. Hospital General Universitario Gregorio Marañón. Instituto de Investigación Sanitaria Gregorio Marañón (IISGM). Madrid, España

OBJECTIVES

Background: Hereditary hemorrhagic telangiectasia (HHT), also known as Osler-Weber-Rendu disease, is a rare, vascular, autosomal dominant disorder. Telangiectasias and Arterio-Venous Malformations (AVMs) of the lung, liver and central nervous system are vascular lesions present in HHT, most commonly causing epistaxis and gastrointestinal bleeding.

OBJECTIVE: To describe the efficacy and safety of treatment with intranasal bevacizumab in HHT.

METHODS

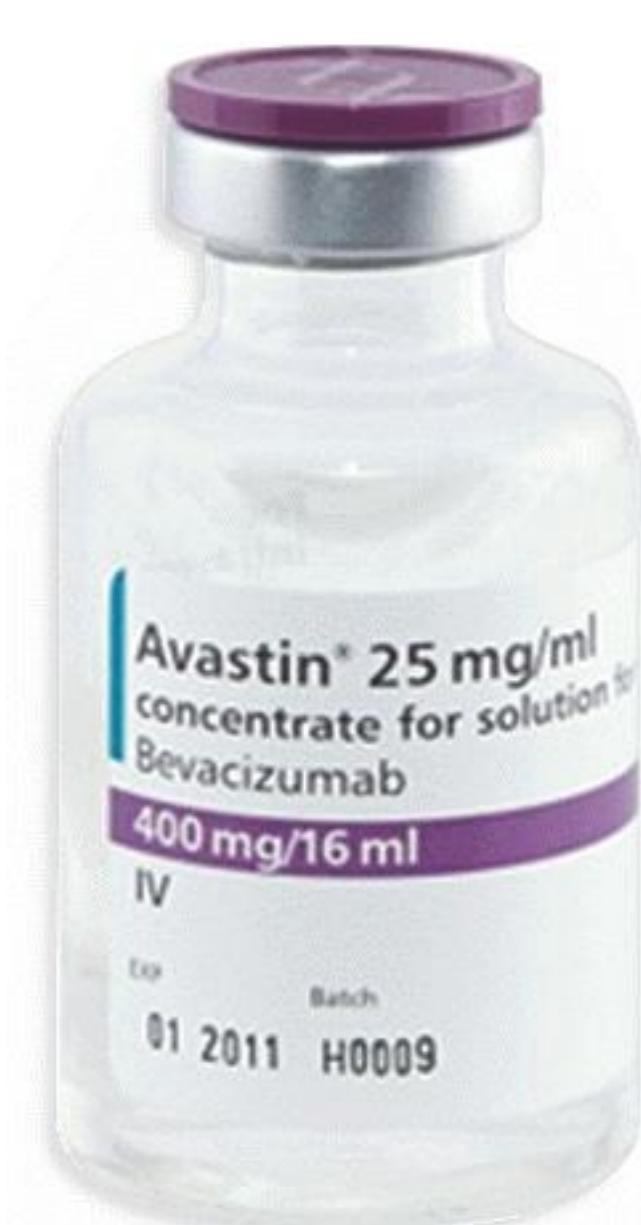A 42 year old woman with HHT, presented with a chief complaint of frequent episodes of epistaxis. She had undergone gingival mucosa cauterization 10 years ago and it solved oral bleeding. Iron studies showed anemia of iron deficiency from chronic blood loss. Initially her anemia was treated with oral ferroproteinsuccinylate. It didn't improve; consequently, physicians replaced her treatment by intravenous iron. She received four blood transfusions in two years. An arterial embolization was carried out in February 2015, it was unsuccessfully.

RESULTS

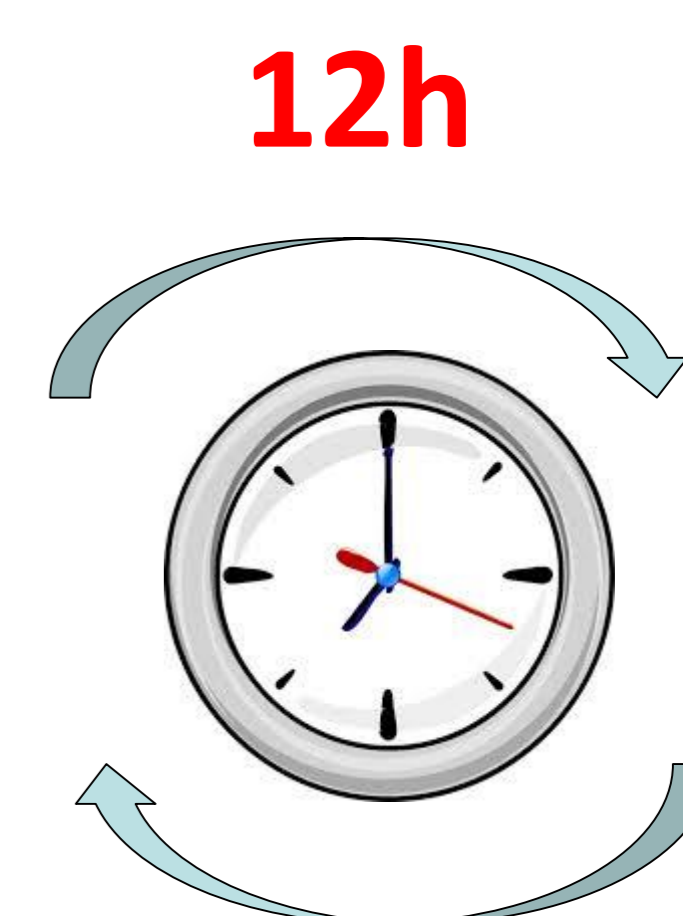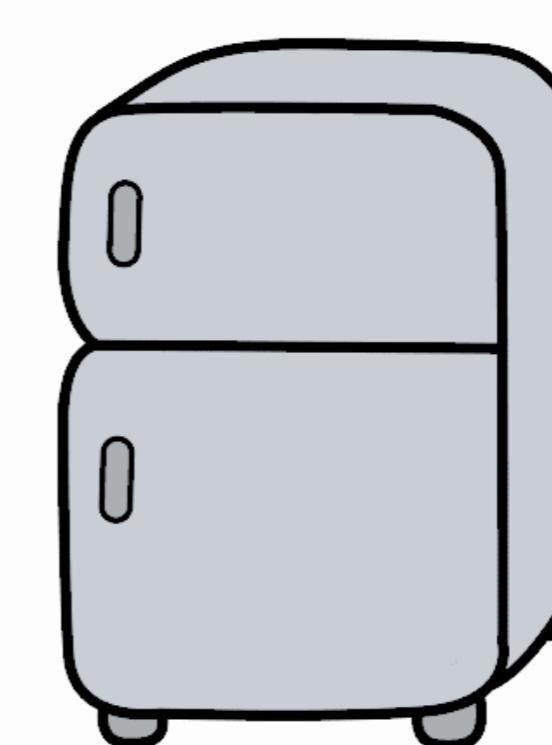
Because of the frequent epistaxis (ESS 6.76) and varying hemoglobin levels (Hb range: 7.7- 9.9) her physicians sought treatment with **intranasal bevacizumab**. The hospital approved this "off-label" use of bevacizumab.

This treatment was elaborated at the Hospital Pharmacy department with Avastin® 400mg/16ml vial in a laminar flow hood. Placed in a nasalspray bottle was 2.5 mL (25 mg). Physico-chemical properties will be stable during the treatment time (21 days) and under refrigeration conditions.

Twice a day was the habitual dosage for two consecutive months. Nasal treatment seemed to control her epistaxis and no adverse effects were reported. She only had few minor episodes of epistaxis, which were easily controlled. The hemoglobin has reached normal levels (Hb range: 12.8-14.1). This has allowed changing the frequency of iron treatment (monthly throughout her maintenance therapy).



Laminar flow hood



21 days

CONCLUSIONS

Vascular endothelial growth factor is a key pathogenic factor that acts to increase and maintain vascular density. To avoid the systemic adverse effects of bevacizumab, intranasal treatment has recently been reported to be a safe alternative to intravenous injection for nosebleeds.

Intranasal bevacizumab is an effective and safe treatment for severe epistaxis in patients with HHT. This therapy reduces epistaxis severity and frequency.

