

PROGRESSIVE MULTIFOCAL LEUKOENCEPHALOPATHY ASSOCIATED WITH FINGOLIMOD USE IN A PATIENT WITH MULTIPLE SCLEROSIS WITHOUT PREVIOUS EXPOSURE TO IMMUNOSUPPRESSANT DRUGS

*G. Calzado, T. Virgós, G. González, J. González, S. Garcia, M. Bullejos, G.J Nazco
Hospital Universitario de Canarias. Pharmacy, Tenerife, Spain*

BACKGROUND

Gilenya (fingolimod) is an immunomodulator which alters the immune system to reduce inflammation. It has been shown to benefit patients with relapsing forms of multiple sclerosis (MS). Progressive multifocal leukoencephalopathy (PML) is a serious brain infection caused by the John Cunningham (JC) virus.

On August 4, 2015, the U.S. Food and Drug Administration announced that a case of definite PML and a case of probable PML had been reported in MS patients taking Gilenya. One of these two cases is described here. It was reported to our reference pharmacovigilance centre and then by the US FDA.

PURPOSE

To report a case of PML associated with Gilenya use.

MATERIALS AND METHODS

The patient was a 54 year-old man diagnosed with MS in 2002 and treated with interferon beta-1b. In 2012, after neurological evaluation, he began a second line of treatment with fingolimod 0.5 mg/24h. He was also taking mesalazine and pitavastatine for ulcerative colitis; none of these drugs are linked to PML. In 2015, the patient was hospitalized with suspected PML after developing new symptoms, including gait instability, clumsiness, inattention, somnolence and mental sluggishness. Gilenya was discontinued.

RESULTS

He was diagnosed with PML based on symptoms, magnetic resonance imaging findings and positive JC virus test in cerebrospinal fluid. Mefloquine, mirtazapine and cidofovir/probenecid were prescribed to treat the PML.

CONCLUSIONS

This is one of very few cases of PML reported worldwide in patients taking Gilenya with no prior exposure to an immunosuppressant drug for MS or any other medical condition. However, no definitive causal relation between Gilenya and the PML has been established. It was classified as conditional using the Karsch-Lasagna algorithm.

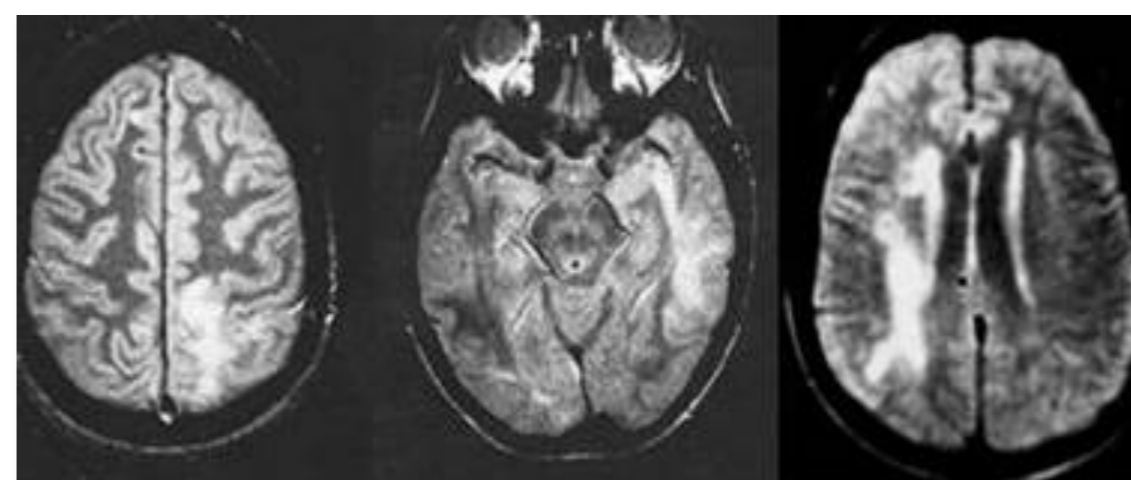


Image 1: Magnetic Resonance imaging in PML

CONFLICT OF INTEREST

The authors have no conflict of interest to declare.