

# DI-048: MANAGEMENT OF CYCLOPHOSPHAMIDE-INDUCED SYNDROME OF INAPPROPRIATE ANTIDIURETIC HORMONE SECRETION IN A PATIENT WITH LIMPHOCYTIC B LIMPHOMA

I. Viguera-Guerra<sup>1</sup>, M.C. Garzás<sup>1</sup>, F. Franco-García<sup>1</sup>.

<sup>1</sup>Hospital Universitario Reina Sofía, Pharmacy Department, Córdoba, Spain.

## Background

Cyclophosphamide is an alkylating agent largely used in hematology. Among its adverse events we found infections, immunosuppression, hypersensitivity reactions, hemorrhagic cystitis and neurologic toxicity. It has also been rarely described the appearance of syndrome of inappropriate antidiuretic hormone secretion (SIADH).

## Purpose

To report a case of SIADH induced by cyclophosphamide in an elder patient with lymphocytic B lymphoma.

## Materials and Methods

87 year-old man was diagnosed of lymphocytic B lymphoma in June 2013.

### TREATMENT

Day 1: **First-line: Chlorambucil** 0.1 mg/kg/day

-> Progression on day 9

Day 10: **Second-line: COP (cyclophosphamide** 750mg/m<sup>2</sup> and **vincristine** 1 mg -> Severe neutropenia (640 cells/mm<sup>3</sup>)

Day 23: the patient was **hospitalised:**

- pneumonia,
- severe hyponatremia,
- decompensated cardiac insufficiency,
- hypoxemia.

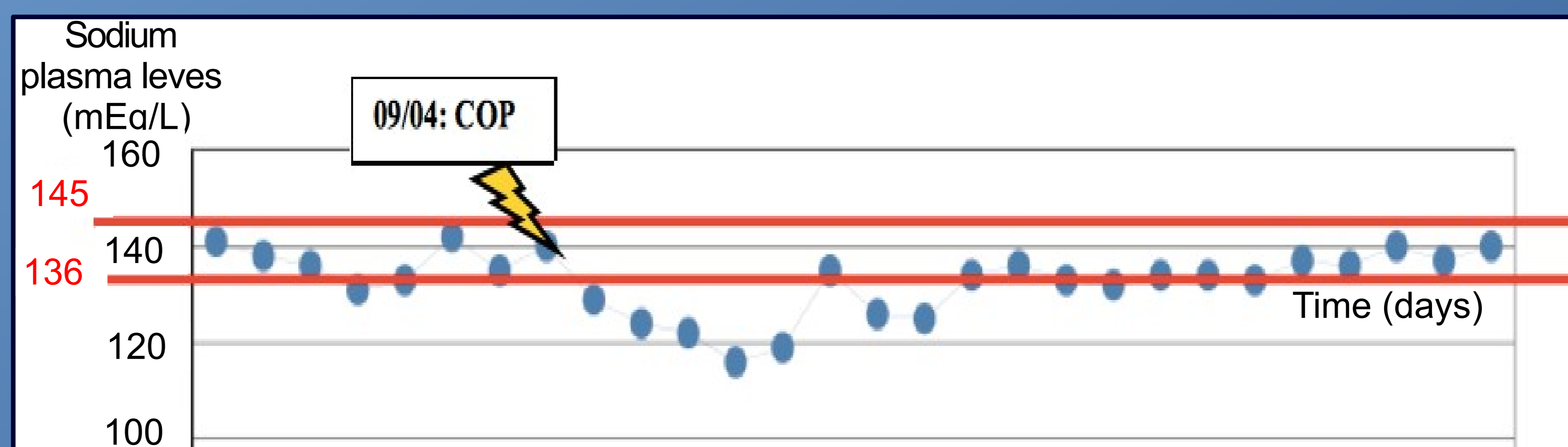


**SUSPECTION OF SIADH INDUCED BY CYCLOPHOSPHAMIDE**

## Results

### LABORATORY

Day 23: [Na+p] = 119 mEq/L,  
[Na+u]=113 mEq/L,  
OsmopP=282 mOsm/Kg.



### TREATMENT

Day 55: **Third-line:** Off-label treatment with **bendamustine** 90 mg/m<sup>2</sup> day 1 and 2, receiving 3CYCLES. Fludarabine was not considered because of history of neutropenia and pneumonia.

### COMPUTERISED TOMOGRAPHY

Day 139: adenopathies had disappeared.

The **ALGORITHM OF KARL-LASAGNA** indicated a **probable** association between SIADH and cyclophosphamide administration.

The case was reported to the **ANDALUSIAN PHARMACOVIGILANCE CENTER** and registered with the number **OL-2819**.

## Conclusions

It is highly important to closely monitor plasma sodium levels during treatment with cyclophosphamide for the possible occurrence of SIADH. Bendamustine treatment in monotherapy provided a safe and effective alternative in this patient.

