

¹L Decarout*, ²M Hermet, ¹M Zenut.

¹Centre Hospitalier Universitaire Gabriel Montpied, Centre Régional de Pharmacovigilance, Clermont-Ferrand, France;

²Centre Hospitalier de Vichy, Service de Médecine Interne, Vichy, France

BACKGROUND

Leukoneutropenia is described in most of the summaries of the characteristics of the products of human intravenous immunoglobulins (ivlg). This side effect is uncommon and not usually described in pediatric populations. Since 1998, less than 200 cases have been reported in the literature.

PURPOSE

The objective was to analyse the causes of two neutropenia occurrences in the same patient successively treated with two ivlg.

MATERIAL AND METHODS

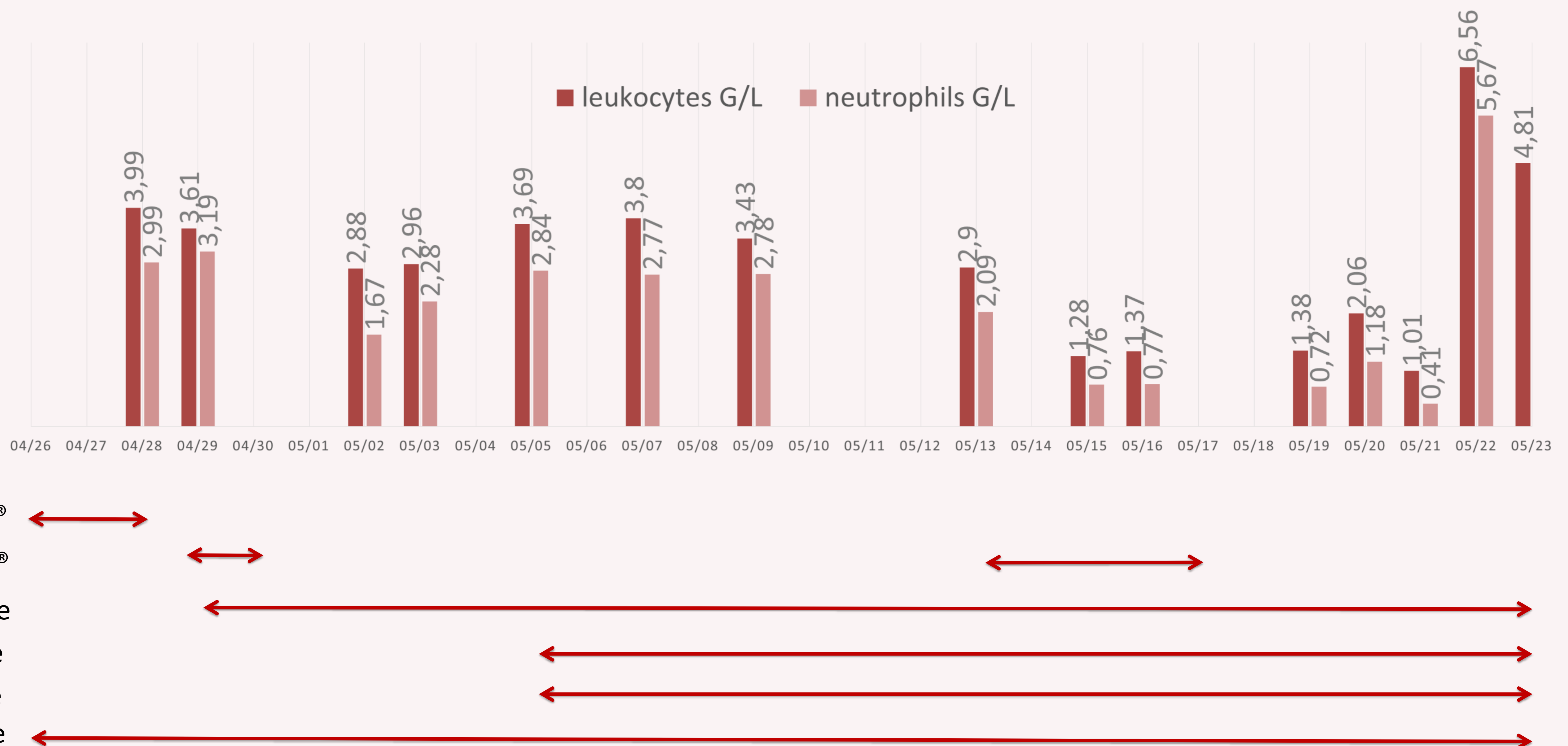
We based our study on bibliography, clinical findings and chronology. The case involved a 77-yearold woman with hypertension and substituted hypothyroidism, who received ivlg and corticotherapy (1 mg/kg/day) for cardiac involvement complicating antisynthetase syndrome.

RESULTATS

A haemogram before therapy was normal. The first treatment with ivlg was administrated as 0.4 g/kg/day for 5 days. Because of procurement difficulty, the patient received special treatment with ivlg (CLAIRYG[®]) for 3 days and special treatment (TEGELINE[®]) over the next 3 days. Clinical and renal tolerance were good but leukoneutropenia appeared after 6 days with leukocytes 2.88 G/L (4–10 G/L) and neutrophils 1.67 G/L (2–7.5 G/L). Leukocyte numbers then improved but without complete normalisation. A second treatment of ivlg (only TEGELINE[®]) was started on day 17. We observed neutropenia (neutrophils 0.76 G/L) on the third perfusion day and agranulocytosis (neutrophils 0.42 G/L) on day 8 without fever but requiring a protector confinement and administration of granulocyte colony stimulating factor. Neutrophils normalized the next day. Vitamins B1, B9 and thyroid function were normal.

A myelogram performed on the day of the agranulocytosis occurrence eliminated the central cause. Methotrexate (15 mg/week) introduced 6 days before the second treatment of ivlg was associated with folic acid supplementation, so its probable toxicity could be excluded. Methotrexate was stopped before the start of the second therapy and was reintroduced 13 days later without agranulocytosis.

Chronology



CONCLUSION

The mechanism of neutropenia was peripheral and it seems that neutrophil anticytoplasm antibodies contained in ivlg formulations could activate TNF-alpha stimulated neutrophils, inducing peroxide production and neutrophil destruction. It spontaneously reversed and did not complicate the infection. These leukoneutropenia are sometimes severe and observed with ivlg. Clinicians should strictly monitor haematological parameters during and after treatment.

Khan S, et al. Intravenous immunoglobulin-induced neutropenia. Pediatr Allergy Immunol 2010;21:892–3.