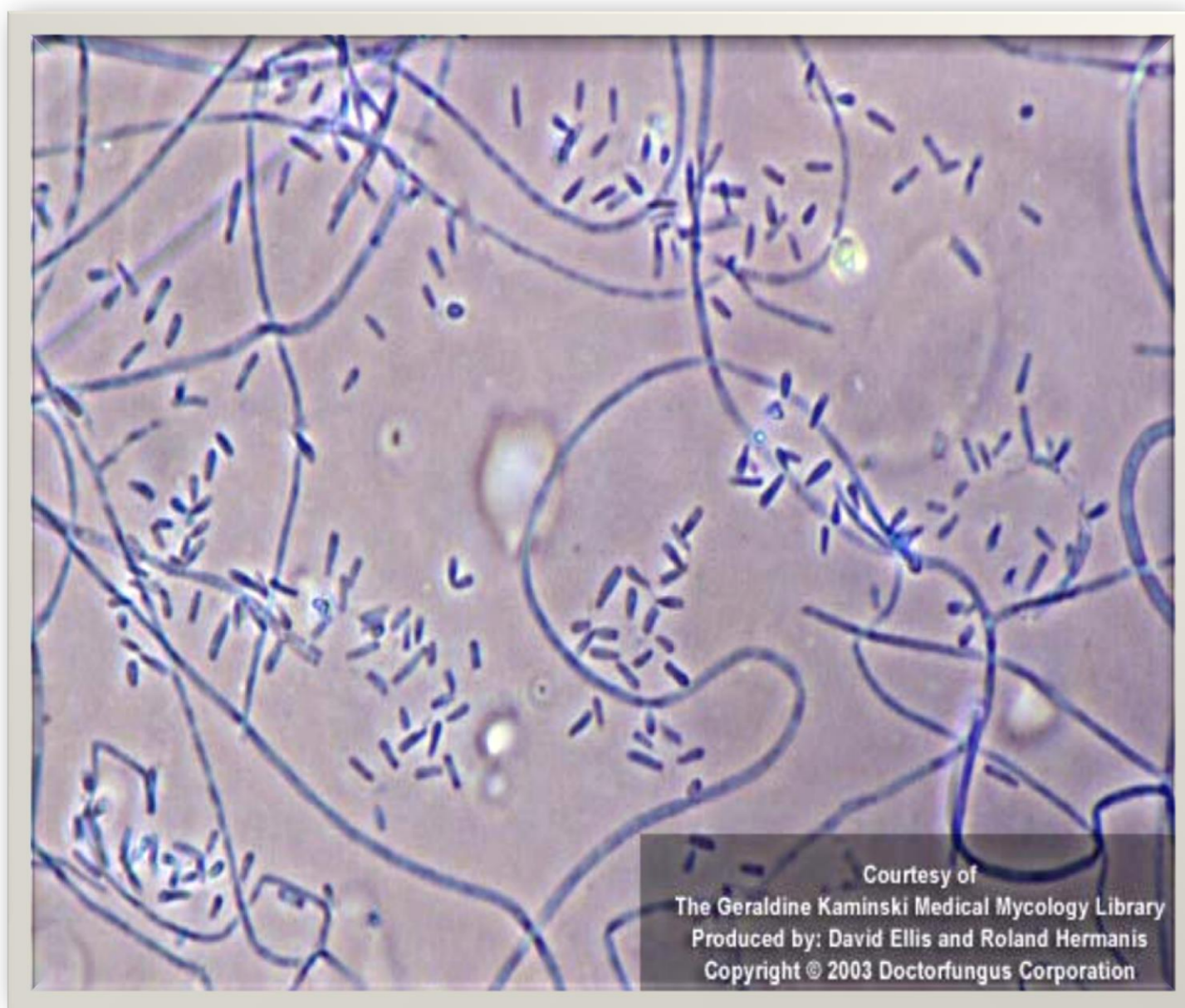


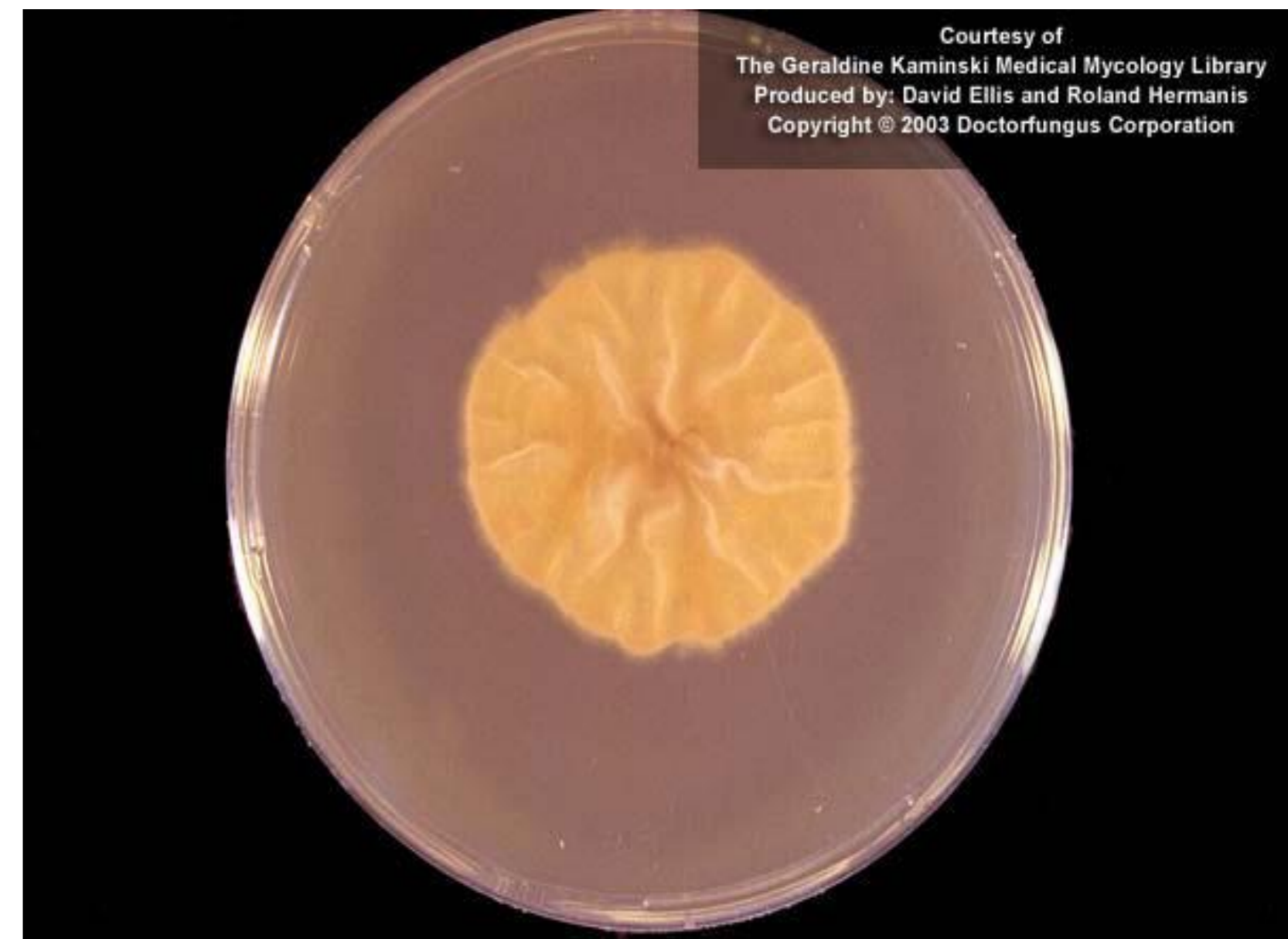Cossío Carbajo F., Martínez-Múgica Barbosa C., Rodríguez Ferreras A., Carriles Fernández C., Álvarez Mancefido F., Rodríguez Palomo A., Llorente Romeo A., Lázaro López E., Martínez Torrón A.

Objective

Description of a case of *kerion celsi* in a girl infected with *Trichophyton verrucosum*.



Microscopic morphology of *T. verrucosum*



Culture of *T. verrucosum* on mycobiotic agar

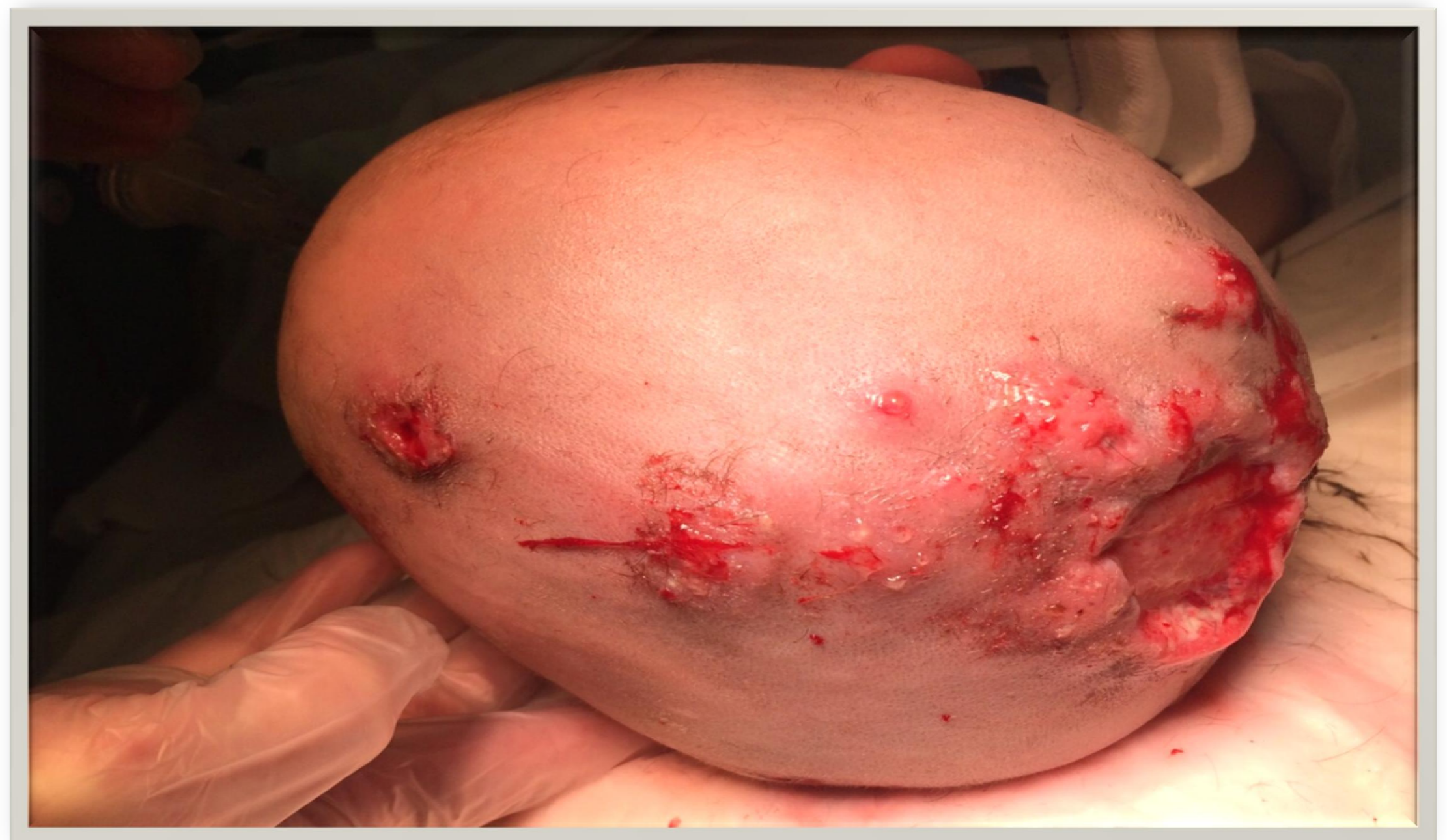Materials and methods

- We report a case of a 2 year old patient who attended the emergency room for a **scalp abscess** caused by trauma on occipitoparietal region with an hematoma at that level. In exploration was observed an abscess with spontaneous drainage holes.

Results and Discussion

Primary Care and Hospital admission

- ✓ Patient was treated firstly with amoxicillin/clavulanate (250/32.5 mg /8h) orally during 7 days.
- ✓ She was admitted into hospital for worsening injury and was treated with antibiotics again, although the bacteriological cultures were negative: Cefuroxime axetil 250 mg /12h orally first and clindamycin 30 mg /kg /day IV after.



Photograph on day 13th after admission

Day 1 to 10

- ✓ The patient injury deepened and spread of 0.5-1 cm plates in left frontoparietal region. It was initiated empirical antifungal therapy for kerion suspicion, griseofulvin 125 mg/ 8h, and also systemic corticosteroid (prednisone 1 mg/kg /day) justified to prevent tissue destruction.
- ✓ Biopsy of the lesion was studied to exclude gangrenous pyoderma or lymphoma, with no results. At the same time, an injury was found in the mother's arm, and was cultured.

Day 10 to 36

- ✓ Unidentified fungus grew so therapy changed to amphotericin B-liposomal IV (5 mg/kg /day) for being broad-spectrum antifungal.
- ✓ On 13th day, the fungus *T. verrucosum* was identified (also in the mother's injury) so antifungal was replaced by topical and systemic terbinafine (125 mg/24h, tablets of 250 mg were split) as treatment of choice for this fungus.
- ✓ Liver test (AST, ALT and LDH) was carefully performed with normal results as terbinafine is off-label for children younger than 4 years. Wounds were healed in the operating room under sedoanalgesia.
- ✓ On day 36th she was discharged with weekly outpatient controls.

Conclusions

- ❖ *T. verrucosum* is a cosmopolitan zoophilic dermatophyte commonly isolated from cattle and horses and the culture growth rate is very slow.
- ❖ The transmission to humans usually occurs by direct contact with infected animals, but can also be spread through contact between people or by sharing personal items.

Aknowledgments

The authors want to thank all personnel in the Pharmacy, Hospital and family of the patient.