

ACHALASIA: A CASE REPORT

Introduction

Esophageal achalasia is a primary esophageal motility disorder characterized by lack of peristalsis and a lower esophageal sphincter (LES) that fails to relax appropriately in response to swallowing. As a result, patients present with dysphagia to both liquids and solids and often suffer from regurgitation.

To improve dysphagia, several treatment options are available including surgical myotomy and endoscopic therapies such as pneumatic dilation or botulinum toxin type A administration.

Botulinum toxin type A, a potent inhibitor of acetylcholine release, poisons the excitatory neurons that increase LES tone allowing evacuation of the esophagus when pressure within the esophagus exceeds that of the paralyzed LES.

Objective

Evaluation of clinical response following administration of botulinum toxin type A in a patient with esophageal achalasia.

Material and methods

We report a case of 85-year-old woman with dysphagia. The patient was admitted to the Orthopedics Department for surgery of a femoral fracture. During the convalescence period, she developed progressive dysphagia of liquids and solids with regurgitation, requiring parenteral nutrition. A gastroscopy was performed which revealed functional stenosis of the LES with normal appearing mucosa. Based on these findings and the clinical presentation, a diagnosis of esophageal achalasia was made. An injection of botulinum toxin type A (Botox[®]) was considered the best treatment option in this elderly patient. Following current legislation regulating the off-label use drugs (RD 1015/2009 and Instruction 05/ 2010 CatSalut), we required patient consent and the authorization of the medical director.

During the second endoscopy, 100 IU of botulinum toxin type A (Botox[®]) were dissolved in 10 ml of saline (10 IU/ml). After the visual assessment of the LES, four intra-sphincteric injections of 2.5 ml of the solution were placed in each of the four quadrants.

Results

The patient noted improved swallowing 24 hours after the procedure and oral intake was initiated. There was no recurrence of the dysphagia at six months follow-up.

Conclusions

The endoscopic findings as well as the clinical response to the botulinum toxin type A use supported the diagnosis of esophageal achalasia. In this case the injections were very effective. The results published in several clinical trials and reviews suggest that the intra-mucosal injection of botulinum toxin type A is a safe and effective endoscopic treatment of dysphagia due to esophageal achalasia. Thus, in patients who for various reasons are not candidates for aggressive treatments such as pneumatic dilation or surgical myotomy, the use of botulinum toxin type A appears to be an excellent treatment option.

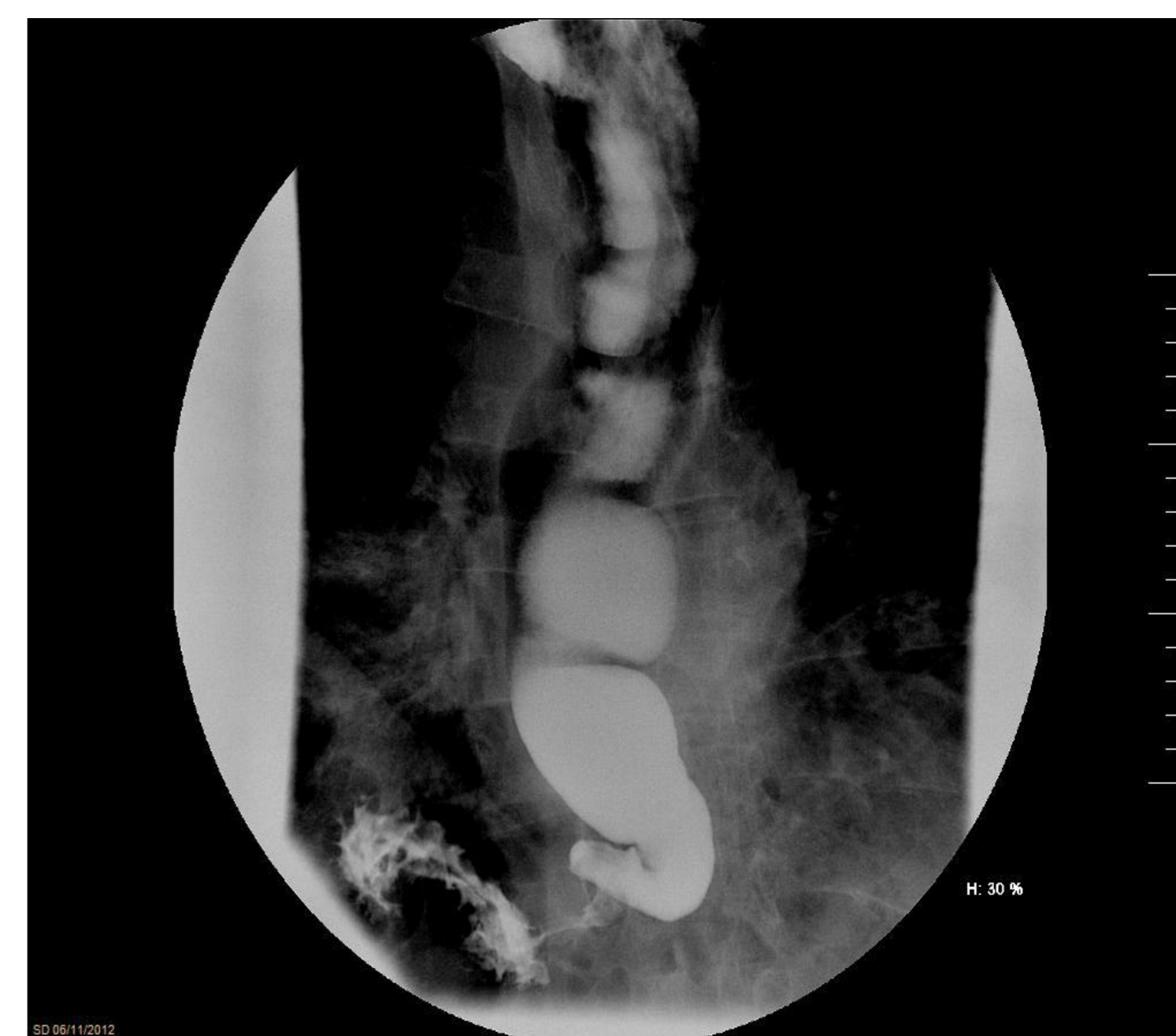

Fig. 1 Barium swallow showing dilated esophagus with retained column of barium and "bird's beak appearance" suggestive of achalasia

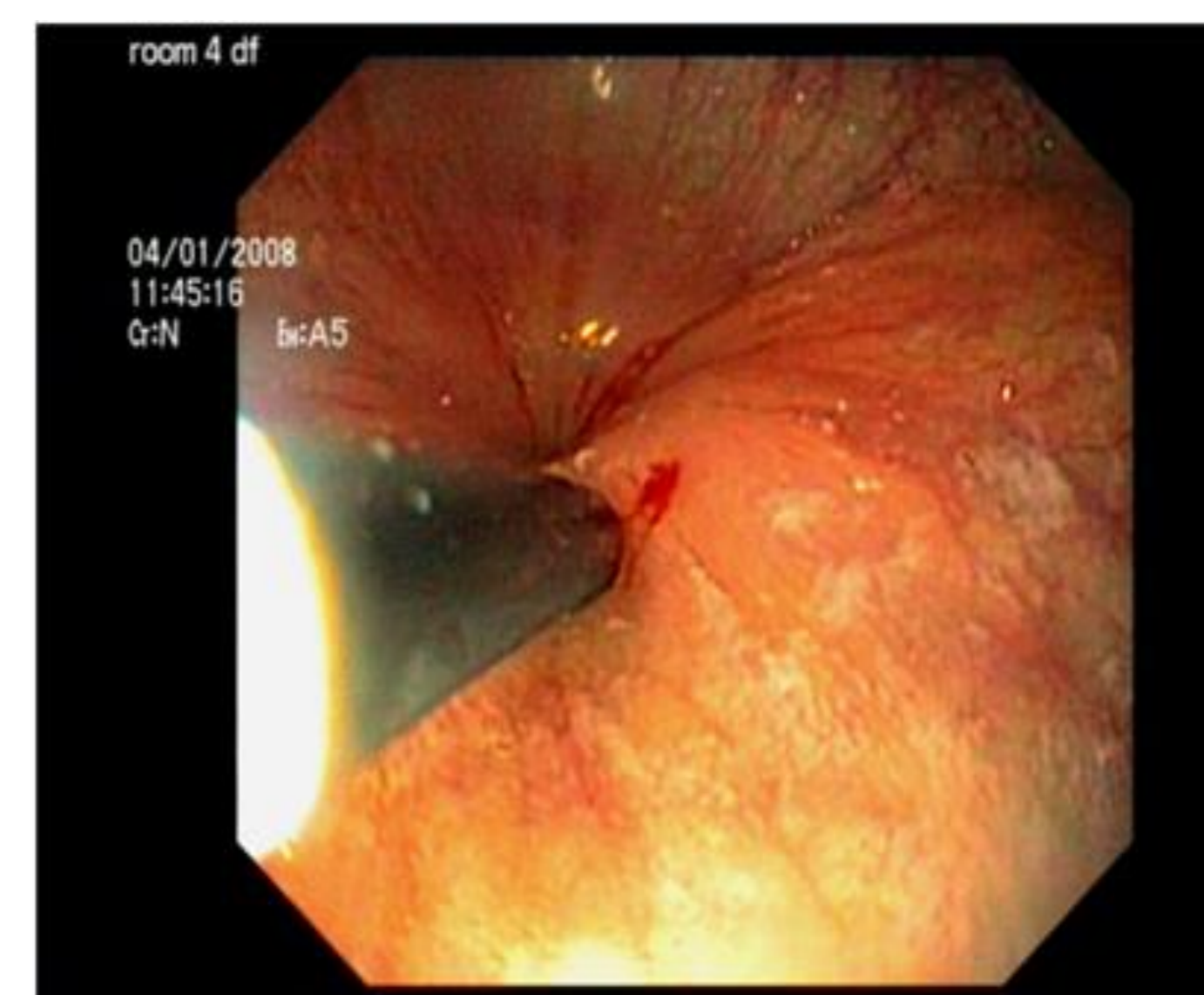


Fig. 2 Intrasphincteric injection of botulinum toxin A for the treatment of achalasia.

Source: T Wataganara, S Leelakusolvong, P Sunsaneevithayakul and C Vantasiri. Treatment of severe achalasia during pregnancy with esophagoscopy injection of botulinum toxin A: a case report. *Journal of Perinatology* (2009) **29**, 637–639; doi:10.1038/jp.2009.65