

INDIVIDUALIZATION OF TREATMENT WITH TOCILIZUMAB IN GRAVES ORBITHOPATHY

A. SÁNCHEZ RUIZ¹, R. CLARAMUNT GARCÍA², C.L. MUÑOZ CID³, Y. JIMÉNEZ LÓPEZ³, E. PÉREZ CANO³.

¹HOSPITAL ALTO GUADALQUIVIR, FARMACIA, ANDÚJAR- JAÉN, SPAIN. ²HOSPITAL VIRGEN DE ALTAGRACIA, PHARMACY, MANZANARES, SPAIN. ³HOSPITAL UNIVERSITARIO DE JAÉN, PHARMACY, JAÉN, SPAIN.
andres.sanchez.ruiz2@Gmail.com

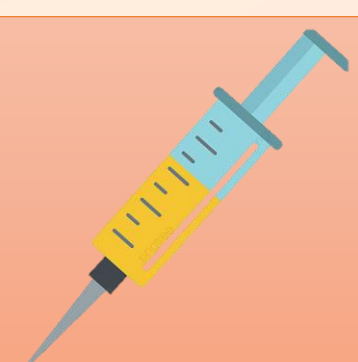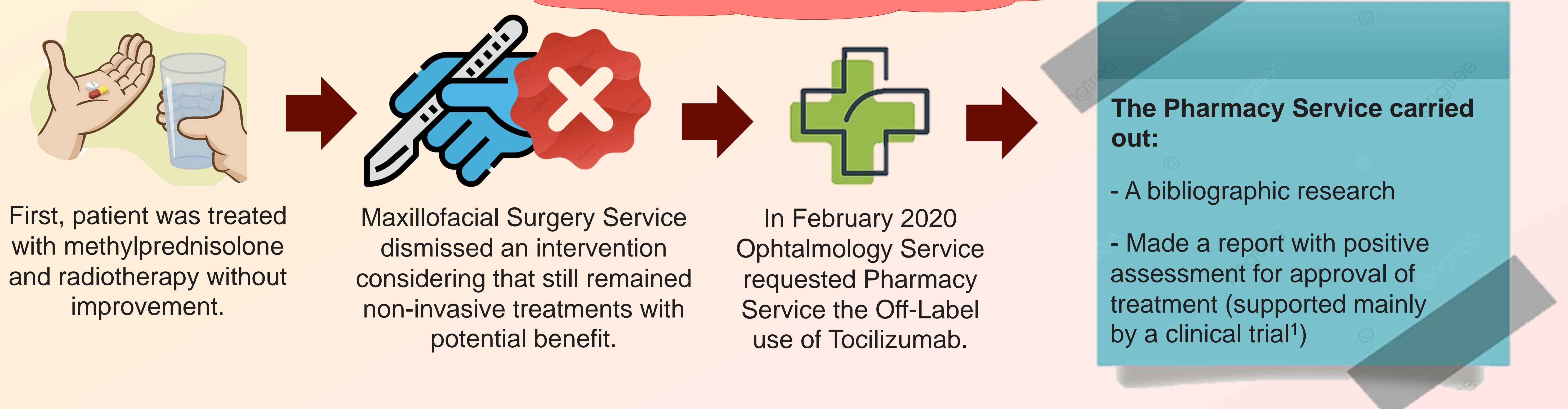
BACKGROUND AND IMPORTANCE

Graves Orbitopathy (OG) is an autoimmune disease and the most common and important manifestation of Graves disease. For patients with moderate-severe disease initial treatment with corticosteroids is recommended. However, some off-label treatments have been used that have suggested efficacy in various cohort studies and case series, such as tocilizumab.

AIM AND OBJECTIVES

We present the case of a 62-year-old male patient. In 2018, Ophthalmology diagnosed OG according to the criteria of the European Group on Graves Orbitopathy (EUGOGO), with greater proptosis in the left eye compared to the right eye (13-17 mm). He also presented polyarthrosis, hypercholesterolemia and hypertension. His treatment included carbimazole, losartan, hydrochlorothiazide, loratadine and atorvastatin. Hyperthyroidism was previously treated with tiamazol.

MATERIAL AND METHODS



Five 8 mg/kg monthly doses of tocilizumab were administered. Finally, at week 44(32 weeks free of treatment) arose the possibility of administering two extra doses.

For the evaluation of the disease, measures such as the Clinical Activity Score (CAS) are used.

RESULTS

A **notable improvement** was observed with the first five doses of tocilizumab, achieving a CAS of 2(low disease activity), with improvement in proptosis(11-15mm) and **good tolerance**. A new improvement was achieved after week 44 over the one already shown with the first five doses and both clinical and analytical parameters (antithyroglobulin levels) improved, with a decrease in the proptosis of both eyes (10-13mm).

The patient reported a good quality of life in the GO-Quality of Life questionnaire.

CONCLUSION AND RELEVANCE

The favorable evolution of our patient is consistent with the published data. We only found one clinical trial and some series of cases, with different dosage of tocilizumab. There still remain doubts about the optimal duration and the possibility of re-treatment with tocilizumab. Collaboration between Ophthalmology and Pharmacy Services is crucial for the rationalization of therapy with tocilizumab.

Bibliography:

1. Perez-Moreiras J et al. Efficacy of tocilizumab in patients with moderate-to-severe corticosteroid-resistant Graves Orbitopathy: A randomized clinical trial. American Journal of Ophthalmology. 2018;195:181–90.