

INTRAVENOUS LEVOMEPRMAZINE IN THE TREATMENT OF CUTANEOUS RASH DUE TO SUSPECTED DRUG HYPERSENSITIVITY: A CASE REPORT

Martín Bartolomé M^{1,3}, Narrillos Moraza A^{1,3}, Salas Parra G^{2,3}, Del Barrio Buesa S^{1,3}, Gómez Costas D^{1,3}, Carrillo Burdallo A^{1,3}, Prieto Romero A^{1,3}, Montero Antón MP^{1,3}, Rioja Díez Y^{1,3}, Herranz Alonso A^{1,3}, Sanjurjo Sáez M^{1,3}.

¹ Pharmacy Department. Hospital General Universitario Gregorio Marañón, Madrid, Spain. ² Allergy Department. Hospital General Universitario Gregorio Marañón, Madrid, Spain. ³ Instituto de Investigación Sanitaria Gregorio Marañón, Madrid, Spain.

BACKGROUND AND IMPORTANCE

Drug hypersensitivity reactions are immune-mediated reactions following exposure to a medication that can be difficult to diagnose. Management involves discontinuing the suspected drug and tailoring treatment to symptom severity, which may include antihistamines, corticosteroids and adrenaline.

AIM AND OBJECTIVE

The aim is to describe the multidisciplinary management of a 19-year-old female with no oral route available who suffered unresponsive cutaneous rash due to suspected drug hypersensitivity.

MATERIALS AND METHODS

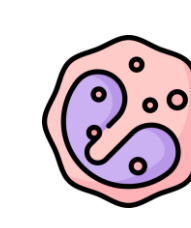
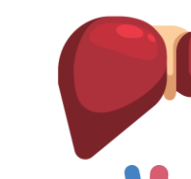
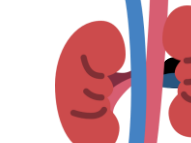
The patient was diagnosed with septic shock and a pseudo-obstructive syndrome. Following surgical intervention and complex pharmacological treatment, the patient developed a severe, pruritic, erythematous rash. Management was as follows:

- 1 IV dexchlorpheniramine was initiated. Administration of β -lactams, sulfonamides and pyrazolones was strictly prohibited.
- 2 IV and topical methylprednisolone were added. Omeprazole, orthopramides, α -adrenergic agonists and macrolides were discontinued.
- 3 Due to the worsening rash and refractory pruritus, allergists consulted the Pharmacy Department to explore alternative IV treatments.

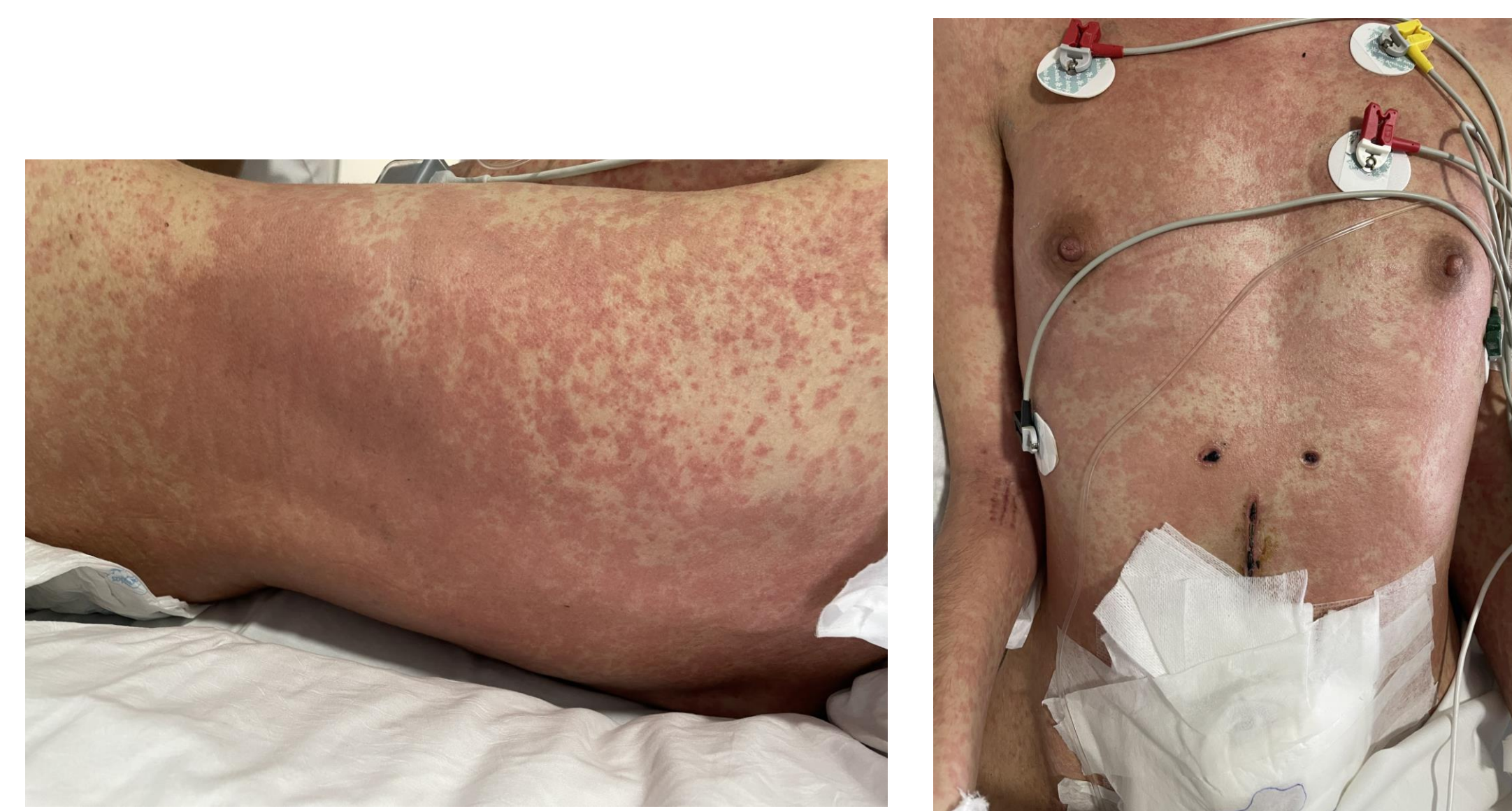

Figure 1. Unresponsive cutaneous rash.

Patient's clinical status was closely monitored:

-  Eosinophil count
-  Liver enzymes
-  Renal function

RESULTS

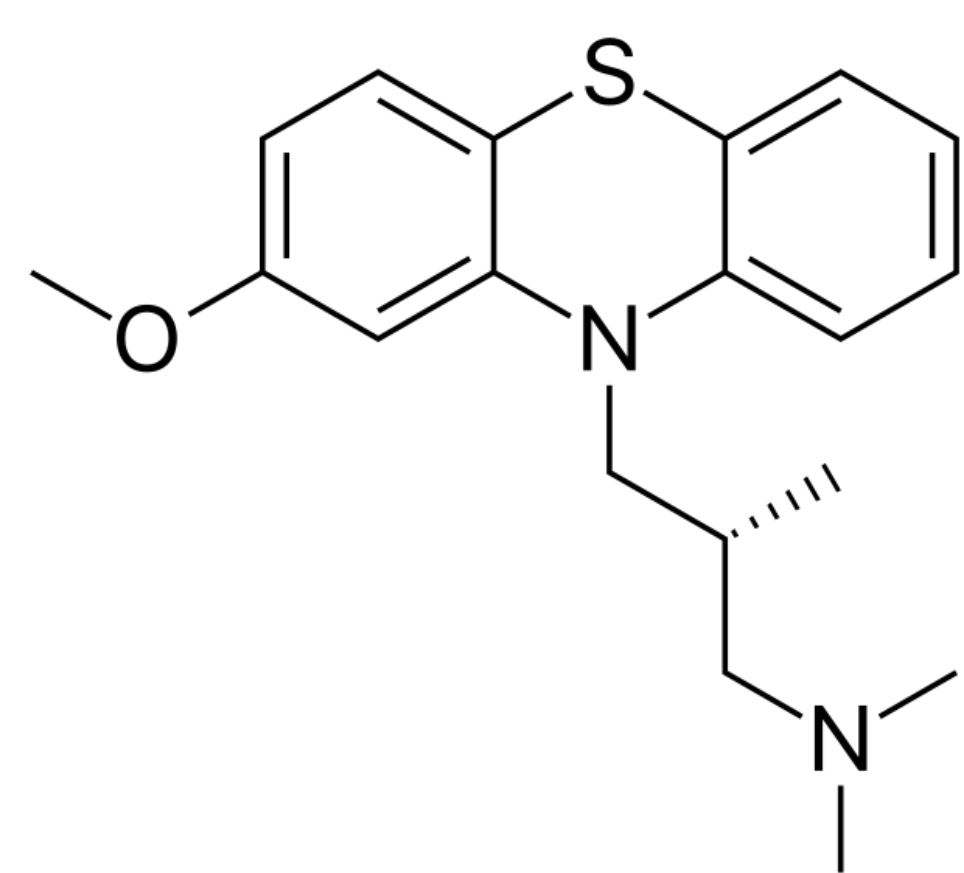


Figure 2: Levomepromazine chemical structure.

Since oral administration was not an option and no IV H1-antagonists were available in our country, other than dexchlorpheniramine, the use of **levomepromazine** was suggested. This drug has a phenothiazine chemical structure, similar to other H1-antagonists. We recommended initiating a continuous infusion of 12,5 mg in 500mL of dextrose 5% under an off-label, compassionate-use scenario.

Soon, the patient showed significant improvement in pruritus, along with a reduction in erythema and rash infiltration, which allowed corticosteroid tapering and the eventual discontinuation of levomepromazine a few days later.

CONCLUSION AND RELEVANCE

This case highlights the potential use of IV levomepromazine in the treatment of refractory drug hypersensitivity reactions. It also underscores the importance of a multidisciplinary approach and contributes to the limited body of literature available.

